

Case report: Successful re-approximation of large oncologic excision on thigh of female patient using DermaClose®

John D. Paletta, MD, FACS. Plastic Surgeon, Savannah, GA.

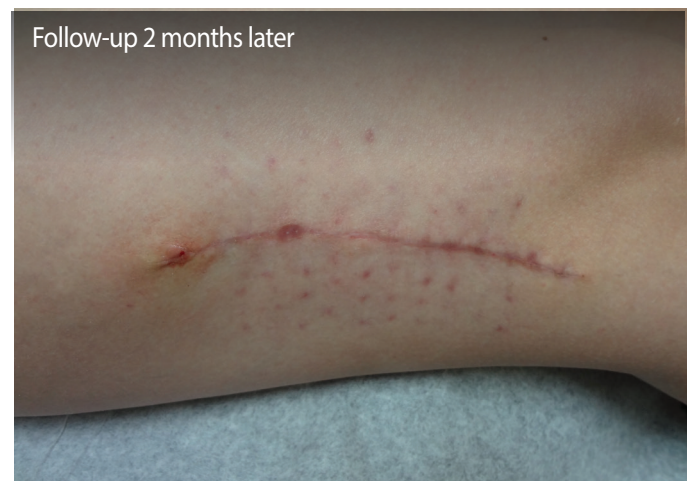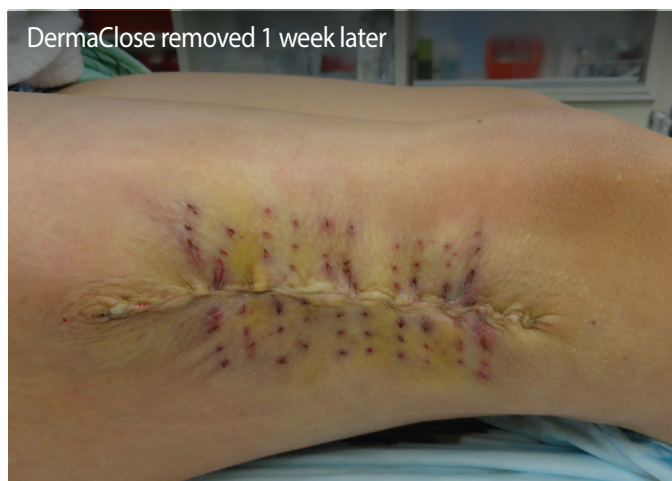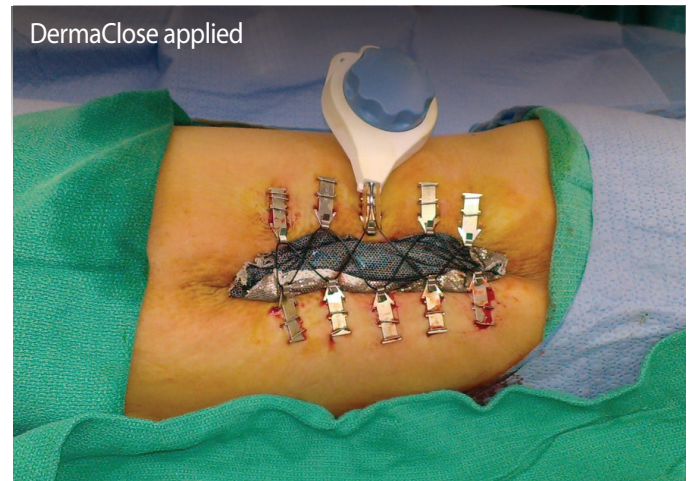
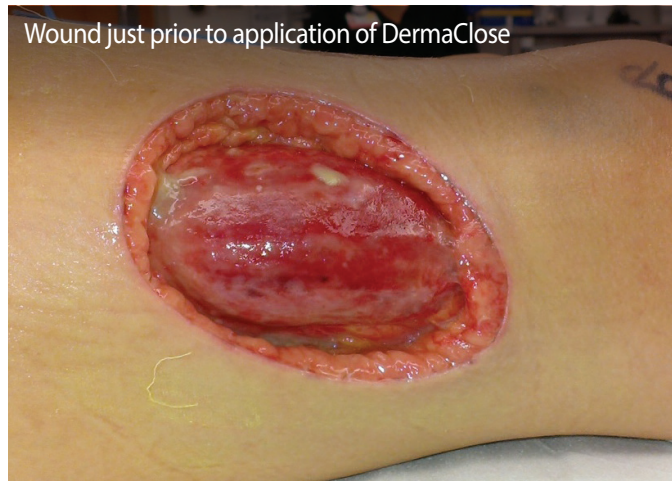Case Report #34

Prior to application of DermaClose: A 25-year-old patient was seen as a follow up after excision of a right thigh lesion. Unfortunately, the pathology showed Dermatofibrosarcoma Protuberans, necessitating a wide local excision.

DermaClose application: The patient was brought to the operating room and underwent a wide local excision. The wound was undermined in a subfascial plane. Ten DermaClose anchors were placed, 5 on each side of the wound and secured with staples.

DermaClose removal: One week later the patient was brought back to the operating room and the DermaClose device was removed. It appeared that the wound could be closed, therefore the wound margins were excised sharply. The skin margins were undermined in the subcutaneous plane and the base of the wound was cleaned with curettes. This was then approximated using 2-0 PDS to approximate the superficial fascial system, 2-0 PDS deep dermal sutures, and 3-0 PDS subcuticular sutures.

Follow-up: During follow up on post-operative day seven the leg looked good and the wound was well approximated. The patient was seen again two months later and was very satisfied with the results.



To schedule a visit by a professional sales representative, please call (800) 896-0436. Learn more at dermaclose.com.