PLASTIC

Case report: DermaClose used to close forehead flap donor site

Dennis J. Hurwitz, MD, FACS - Plastic Surgeon - Pittsburgh, PA

Case report #27:

2/25/2012 - This 53 year old patient had presented three days earlier when a large basal squamous cell carcinoma of the nose was removed. At the end of that operation and again today there is no evidence grossly of persistent tumor nevertheless the carcinoma was adherent to the nasal dorsum cartilage and boney periosteum. For tumor control and aesthetic reconstructive considerations near complete excision of the skin muscle upper lateral cartilages and lower portion of the nasal bones was indicated. This was explained in detail to the patient who knew of the need for a wide excision in the anticipated forehead flap and auricular cartilage reconstruction. The lesion was excised with the excision measuring 6 x 8cm in size. Electrocautery was used for hemostasis. The patient tolerated the procedure well. We will plan to do a forehead flap to close the nasal wound once the pathology report is received.

2/29/12 - Four days earlier the patients entire nasal dorsum extending onto the left cheek with skin flaps had been removed, along with his left upper lateral cartilage and a portion of his nasal bones. He needed resurfacing of the entire bridge of the nose and skin flaps. The pathology report indicated a pigmented lesion in the central forehead right where the forehead flap was to be taken. This needed to be excised as a skin cancer while we harvested the inferiorly based forehead flap for nasal reconstruction. The resulting gap is so wide at 6 cm that direct closure of the donor site was not possible and therefore we inserted the DermaClose external tissue expander. The intraoperative dynamic force delivered by the DermaClose while the flap was sewn in place reduced the defect to approximately 2mm. Skin tension was still too tight for closure so the device was left in place with the patient to return in 48 hours. Patient tolerated the procedure well.

3/6/12- At six days post-op the patient was seen at my office and with the wound edges approximated nicely, the DermaClose device was removed and the incisional wound was left to heal by secondary intention. The incisions are clean, dry, intact, and healing well. There are no signs of infection, seroma, hematoma, necrosis, or dehisence. The flap is intact and viable with good blood supply. There is moderate swelling and bruising. Patient is doing well and is happy with the results thus far.

3/21/12 - At three weeks the patient returned for division and in-set of forehead flap to the nose. The flap donors site has healed nicely and the patient is happy with the results.

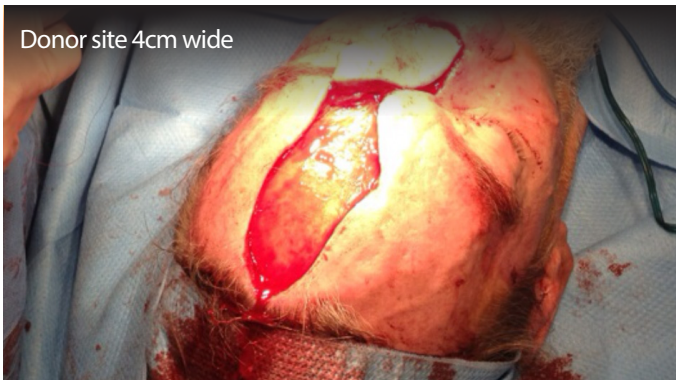
Donor site 4cm wide

Intraoperative wound reduction

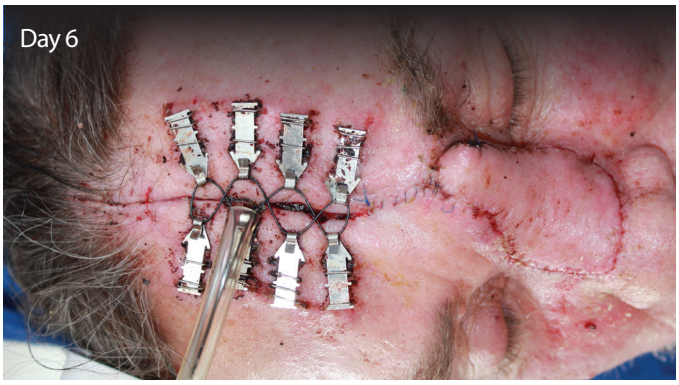
Day 6

At three weeks wound healed nicely

To schedule a visit by a professional sales representative, please call (800) 896-0436. Learn more at dermaclose.com.

wct inc. Expanding Your Clinical Options™

Manufacturer
WCT inc.
1721 Lake Drive West
Chanhassen, MN 55317

(800) 896-0436
dermaclose.com
© 2014 Wound Care Technologies, Inc.
PR-0042_B

DermaClose® Continuous External Tissue Expander