

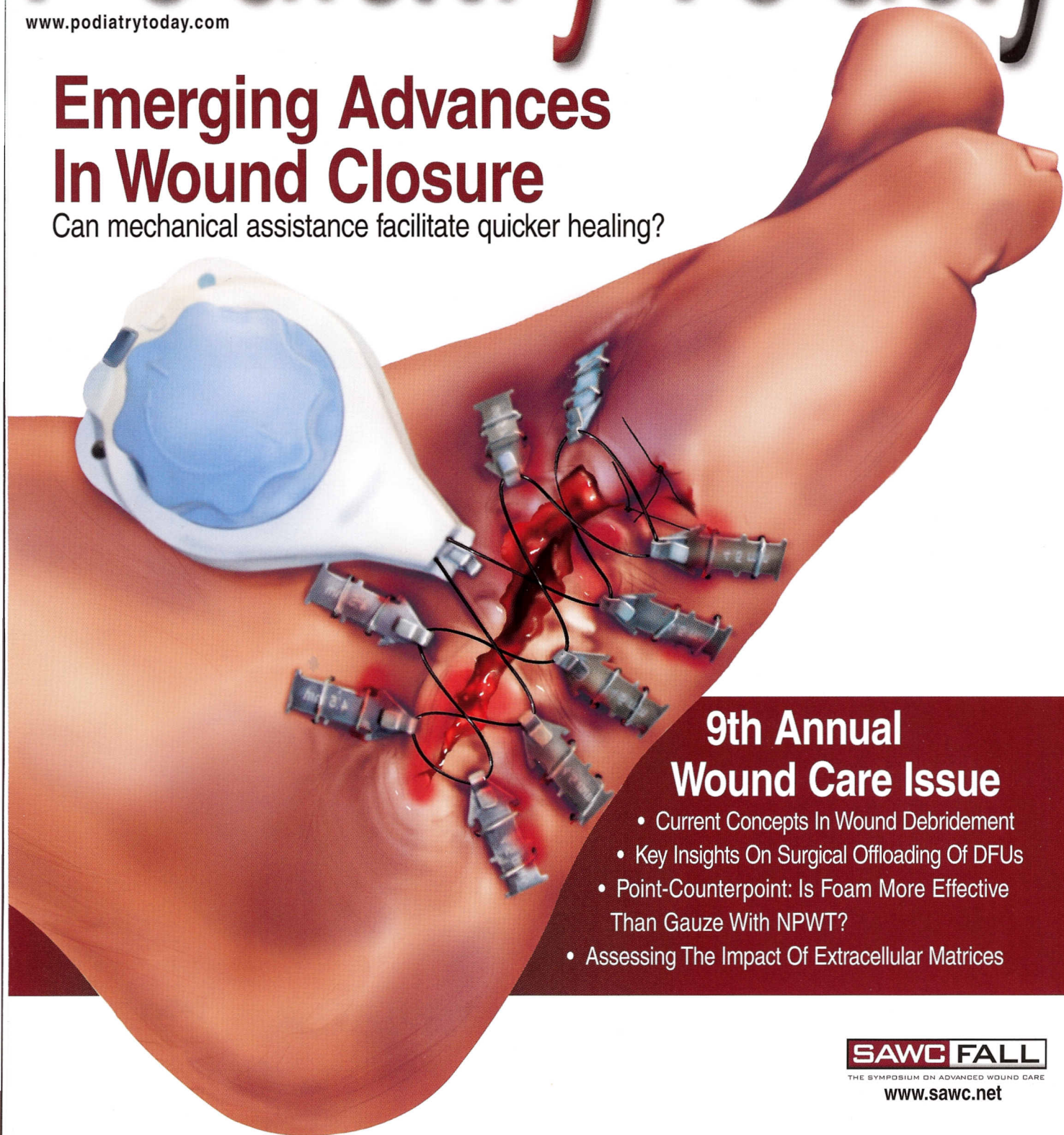
July 2009

Podiatry Today

www.podiatrytoday.com

Emerging Advances In Wound Closure

Can mechanical assistance facilitate quicker healing?



9th Annual Wound Care Issue

- Current Concepts In Wound Debridement
- Key Insights On Surgical Offloading Of DFUs
- Point-Counterpoint: Is Foam More Effective Than Gauze With NPWT?
- Assessing The Impact Of Extracellular Matrices

SAWC FALL

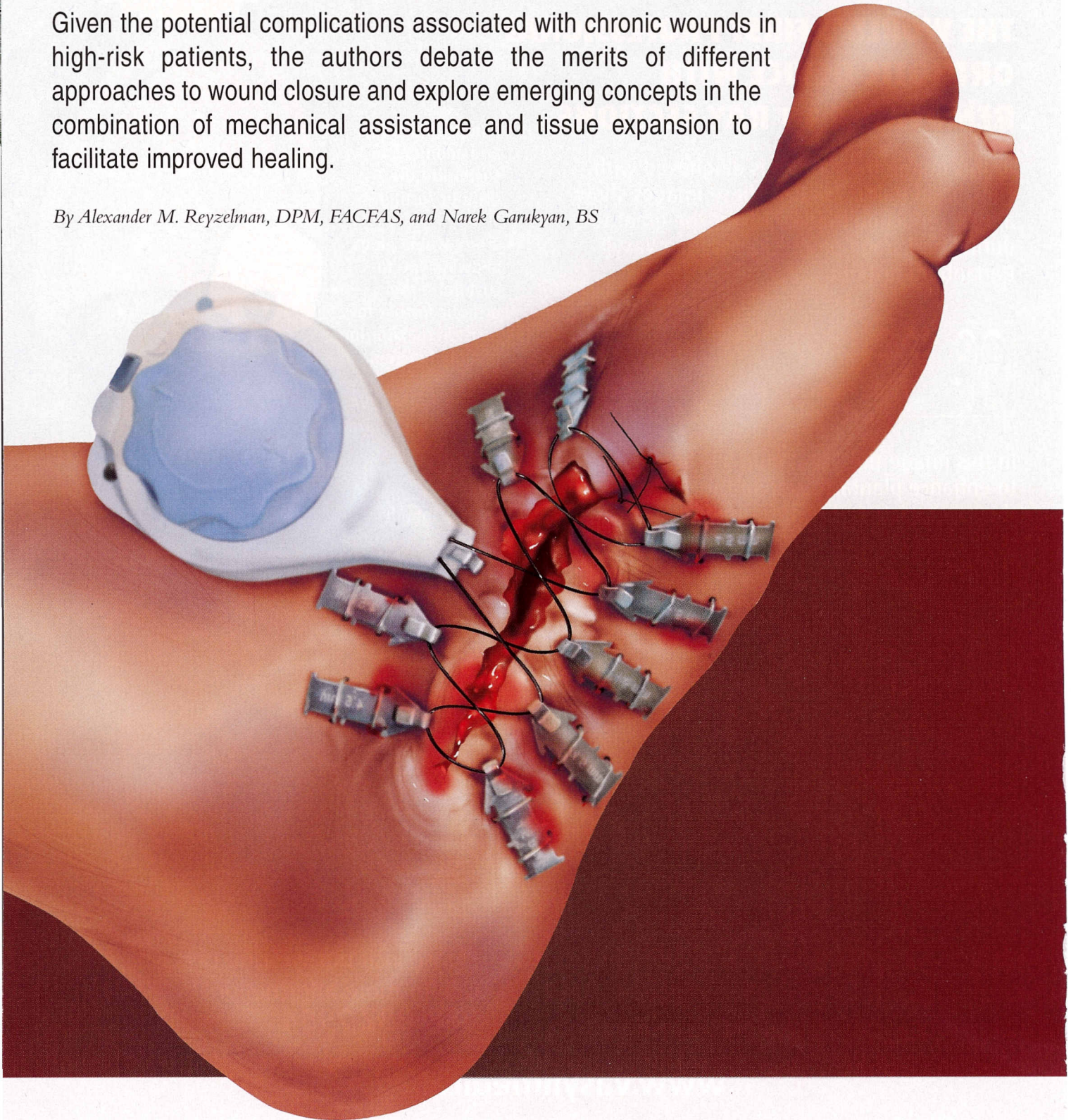
THE SYMPOSIUM ON ADVANCED WOUND CARE

www.sawc.net

Emerging Advances In Wound Closure

Given the potential complications associated with chronic wounds in high-risk patients, the authors debate the merits of different approaches to wound closure and explore emerging concepts in the combination of mechanical assistance and tissue expansion to facilitate improved healing.

By Alexander M. Reyzelman, DPM, FACFAS, and Narek Garukyan, BS



An estimated 15 percent of patients with diabetes will develop a lower extremity ulcer during the course of their disease. In addition, foot ulceration is the precursor to approximately 85 percent of lower extremity amputations in people with diabetes. Moreover, there is a 50 percent incidence of a contralateral amputation within two to five years of a lower extremity amputation.¹

Treatment of infected foot wounds comprises up to one-quarter of all diabetes-related hospital admissions in the United States and Britain. Accordingly, it is the most common reason for diabetes-related hospitalization in these countries. People with diabetes have an increased risk of developing an infection of any kind and a several-fold risk of developing osteomyelitis. The same risk factors that predispose people to ulceration are also generally considered to be contributing causes of amputation.¹

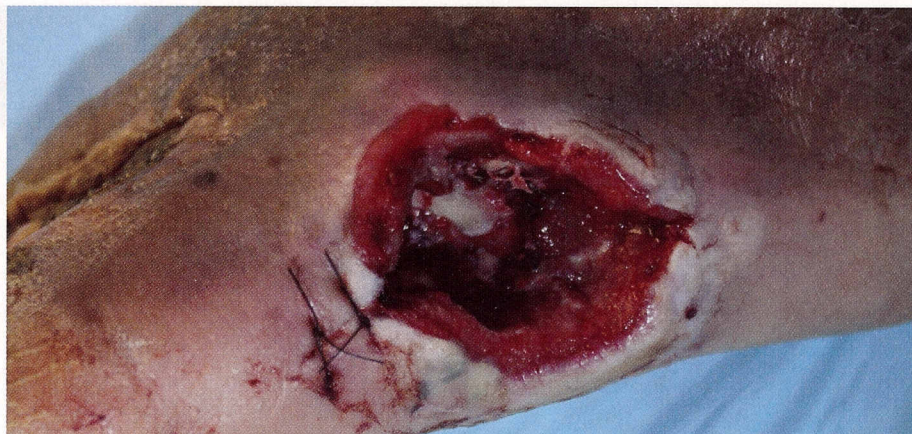When a limb-threatening infection is present, early surgical treatment of the affected site is typically necessary as an integral part of infection management.¹

The skin is the most important barrier against infection. It is well documented in the literature that people with diabetes have compromised immune systems. Therefore, their infection fighting capability becomes a real challenge. Obtaining wound closure is paramount in avoiding the additional complications associated with a chronic open wound.² Primary or delayed primary closure is ideal in achieving wound closure and decreasing the likelihood of a recurrent infection.

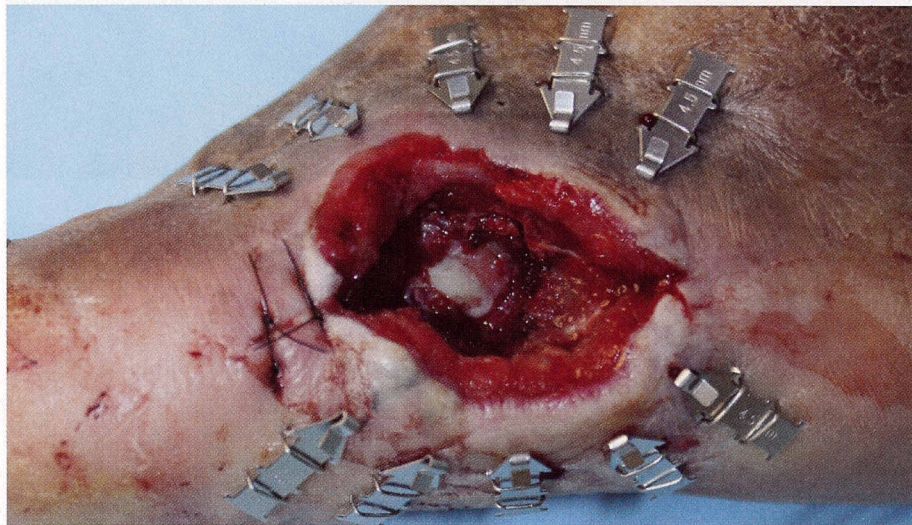
Should You Opt For Primary Closure, Delayed Primary Closure Or Closure By Secondary Intention?

Primary closure involves the reapproximation of viable skin, most commonly involving the use of sutures.² Obtaining primary closure after debridement and/or partial foot amputations is ideal. Primary closure reduces the risk of infection by providing a skin barrier to the potential pathogens. However, wound care surgeons are constantly faced with the dilemma of whether they should leave the wound open or close it primarily.

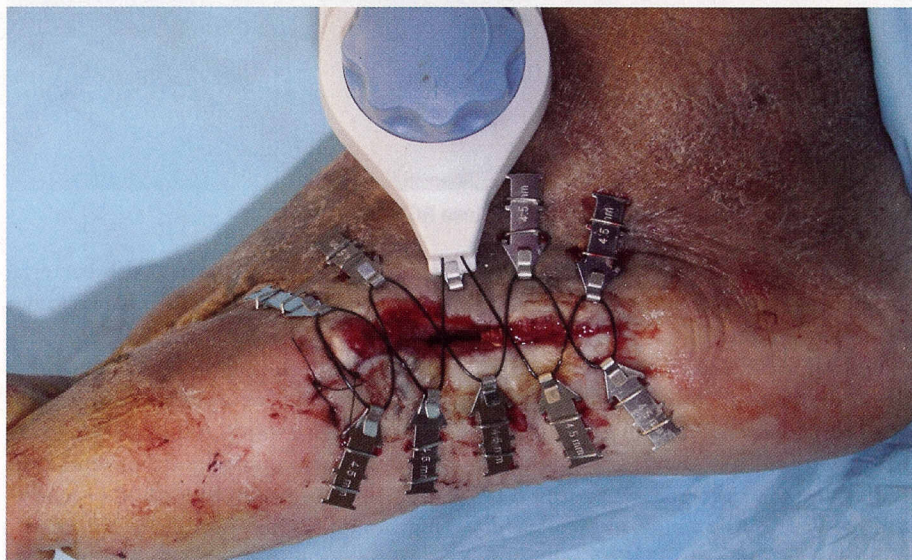
At our institution, we approach the question of leaving the wound open or closing it as follows: If we perform the surgical procedure on a semi-elective



Here can see a large open wound following deep debridement. The wound cannot be closed primarily.



Surgeons have applied skin anchors to the large open wound.



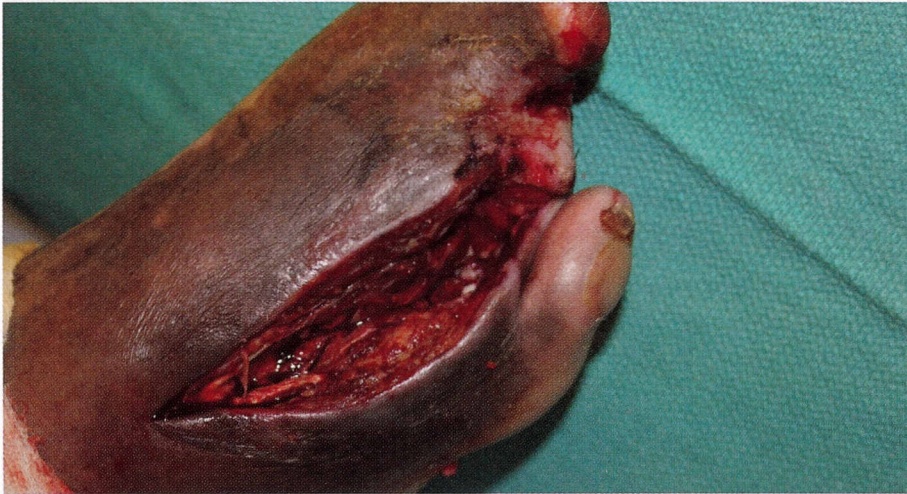
In this photo, one can see the foot immediately after application of DermaClose RC.

basis (the need for an amputation without the presence of an active infection), then we make every effort to close the wound primarily.

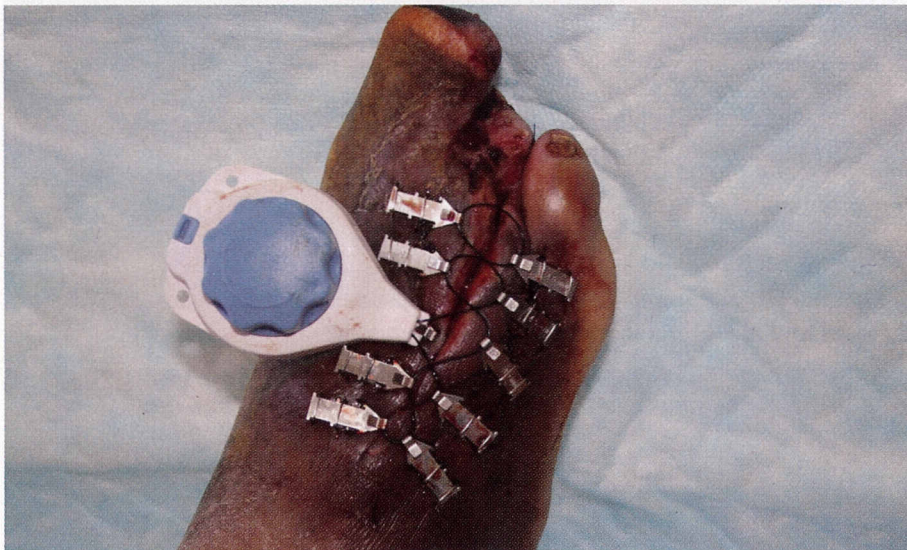
However, if we are performing a partial foot amputation, or an incision and

drainage (I&D) procedure due to either an acute or chronic foot infection, we almost always leave the wound open for at least two to five days prior to attempting delayed primary closure. Leaving the wound open for two to five days allows us

Wound Closure



Here is an open wound following a partial fourth ray amputation.



Here is the wound several hours after DermaClose RC application.

to perform local wound care and evaluate the wound for any signs of a residual infection/necrosis.

During these early postoperative days, the administration of intravenous antibiotics continues and helps in preparing the open wound for delayed closure. We found that this management process leads to lower readmission rates and less recidivism of infection.

In situations in which there is viable tissue and the podiatrist is certain he or she has removed all infected tissue, he or she may opt to perform delayed primary closure. Surgeons usually perform delayed primary closure three to five days after the initial ablative procedure.² In this time interval, the patient's natural defenses and

antibiotic treatment reduce the bacterial load, therefore reducing the chance for an infection or re-infection.²

There are other forms of wound closure that include various types of rotational skin flaps and skin grafting. Although skin grafting is an option, utilizing the patient's own skin is still the preferred method of achieving wound closure.

However, one cannot close all wounds via primary closure or delayed primary closure techniques. Some wounds will heal by secondary intention.² Closure by secondary intention involves allowing the wound to form granulation tissue and reepithelialize.² One may utilize this option after an I&D procedure, after deep/aggressive debridement of bone or

when there is not enough healthy tissue to perform delayed primary closure.

Although this is not the ideal method of achieving healing, it is probably the most common method of wound healing used today. We utilize secondary intention healing on daily basis. However, it is the one technique that carries a high rate of infection due to the lack of skin barrier.

A Closer Look At Mechanical Assistance And Tissue Expansion

Mechanical assistance through the use of a variety of skin stretching devices to facilitate tissue expansion is an option to help the surgical wound care specialist achieve wound closure.¹

Researchers have studied tissue expansion as an aide in the rapid closure of wounds after ulcer debridement, bone resection and amputation.³ Studies have shown that mechanically assisted wounds close up to 40 percent faster in comparison to wounds left to heal by secondary intention.⁴ Mechanically assisted wound closure with tissue expansion can also be a viable alternative to skin flaps and skin grafting.

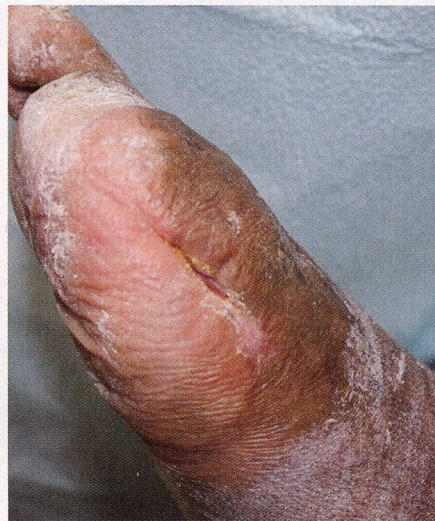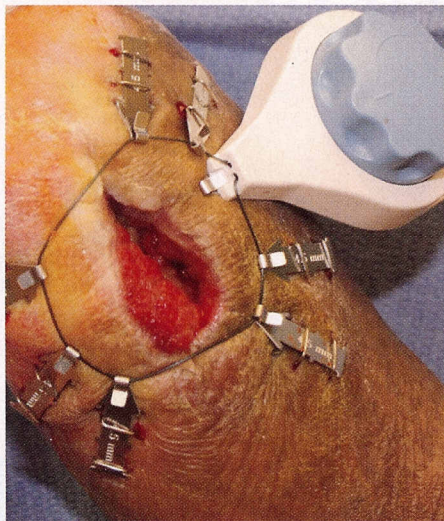
The viscoelasticity of skin has two properties: creep and stress relaxation. Creep can be either biological or mechanical.

Biological creep occurs when the slow application of a subcutaneous force causes expansion of the skin. Examples of biological creep are obesity, a tumor or a growing fetus.

Mechanical creep occurs when skin stretches beyond its normal extensibility in a shorter period of time. With mechanical force, dermal collagen fibers that normally exist in a convoluted pattern become straightened, the tissue fluid and polysaccharide ground substance become displaced, and the additional surface area enlarges.⁵

Examples of mechanical creep are pre-suturing and the Sure Closure Skin Stretching System (MedTech Group and Zimmer Orthopaedic Surgical Products).⁶ Sure Closure involves the use of two K-wires that run through the dermis on opposite sides of an open wound.¹ Each end has a threaded rod

Wound Closure



The photo on the left shows the DermaClose RC device applied to the wound. The right photo shows the healed wound.

that attaches to the K-wires by a special threaded nut and holds the K-wires parallel to one another.⁶ As one tightens the two K-wires toward each other, the attached skin edges approximate. The surgeon performs this over a period of days, ensuring continual intermittent tightening of the apparatus until he or she has obtained closure.⁶

However, the Sure Closure unit has some associated complications such as necrosis of the skin edges, scar hypertrophy, wound dehiscence and incomplete closure.⁶ In the senior author's opinion, due to these complications, Sure Closure Skin Stretching System never realized its potential in the wound care arena.

The stress relaxation property of viscoelasticity is evident when skin stretches for a period of time and then relaxes. Performing this cyclic loading and unloading is known clinically to cause tissue expansion.⁶ Examples of this technique include the use of silastic balloons in either prolonged tissue expansion or rapid intraoperative tissue expansion, and the Sure Closure procedure.

Can A New Device Help With Wound Closure?

Recently, podiatrists have started using DermaClose™ RC (Wound Care Technologies) to facilitate the closure of lower extremity wounds.

Plastic surgeons have used this product for tissue expansion. Small to large skin voids occur commonly in plastic surgery following the removal of cancer affected areas of the skin, excision of tissue and debridement of dehisced wounds.⁷ By using the DermaClose RC tissue expander, surgeons have obtained rapid closure of skin deficits with success and less scarring following these procedures.

This procedure involves placing specially designed skin anchors equidistant in a circumferential pattern around an ulcer or wound. Then the surgeon would run a monofilament around the anchors in a lace-like pattern. Proceed to tighten the monofilament to a preset tension of 1,200 g with an attached tension controller. The tension is automatically constant and one does not need to make any further adjustments until the wound edges approximate within one to five days.⁷

To date, there have been over 200 applications of this device. Recently at the Symposium on Advanced Wound Care (SAWC) conference in Dallas, Hanft et al., presented an oral abstract of a retrospective analysis of 25 wounds that underwent closure via DermaClose RC. The mean duration of the device application was three days and the mean duration for the wound margin approximation was 12 days. The mean area

reduction was 86.9 percent +/- 14 percent with device application and the mean velocity of healing was 22.6 cm² per day.⁸

At our institution, we retrospectively reviewed six patients who were treated with the DermaClose RC device. The mean area of reduction we obtained in our subset of patients was 79 percent. Our mean time of application was 28 hours.

There are several pearls to consider when using this device.

- When using DermaClose RC on chronic wounds, one must create an acute wound via an aggressive debridement of both the base of the wound and its skin margins.
- When dealing with a chronic open wound which has skin margins that are well adhered to the granulation tissue base, one must undermine the margins by at least 1 to 1.5 cm in order to allow the skin stretching to occur.
- One can apply DermaClose RC for anywhere from several hours to one week. The duration of time in which DermaClose RC will be needed is based on the wound size and patient compliance.

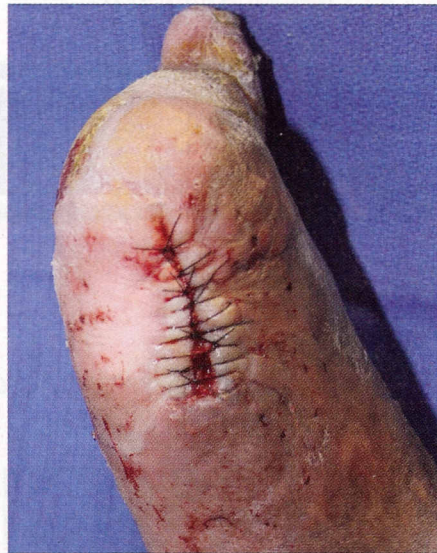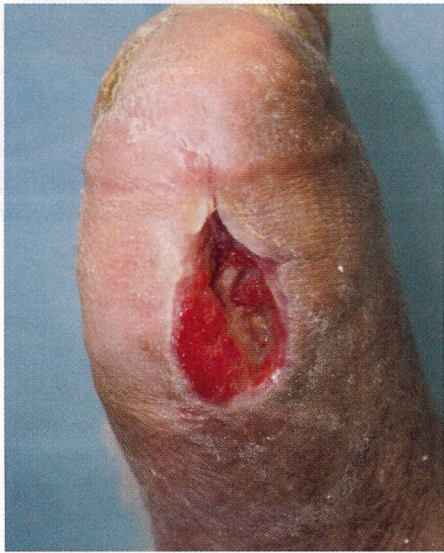This novel device facilitates closure of a wound using the skin's natural ability to respond to the stress applied by stretching. When one uses the device properly, DermaClose RC can help close more wounds that otherwise would be left open and allowed to heal secondarily, or would go on to skin grafting.

Case Study: When A Patient With Diabetes Has A Partial First Ray Amputation Due To An Infected Ulcer

The patient is a 58-year-old male who has had diabetes for 20 years. He developed an ulcer on the plantar aspect of the right hallux, which eventually became infected and required a partial first ray amputation. Due to the severity of the infection, surgeons left the amputation partially open.

The patient's past medical history was significant for diabetes, chronic renal insufficiency, peripheral arterial disease,

Wound Closure



The left photo shows an open wound of a 58-year-old patient with diabetes who developed an ulcer that became infected. Surgeons left the resulting amputation open due to the infection's severity. On the right, one can see the delayed primary closure that occurred immediately after the removal of DermaClose RC.

coronary artery disease, hypertension, hypercholesterolemia and peripheral neuropathy.

At the time of the evaluation, the patient had undergone an open partial first ray amputation a year earlier. His physical examination findings consisted of palpable pedal pulses, absent protective threshold and elevated vibratory perceptive threshold.

The wound was at the distal aspect of the amputation site with viable margins and wound base that appeared healthy. There were no exposed tendons or bone. Radiographs were negative for osteomyelitis.

Based on the chronicity of the wound and the lack of clinical and radiographic findings of an underlying infection, the surgeon decided to apply the DermaClose RC device to assist in delayed primary closure. Prior to application of the device, the surgeon debrided the wound in order to remove the biofilm and the chronic granulation tissue.

The patient ambulated in a post-op shoe while using the DermaClose RC device. The patient returned 24 hours later. At this time, the skin margins were very closely approximated and the surgeon removed the DermaClose RC device. Immediately after the removal of

the DermaClose RC device, the surgeon performed delayed primary closure utilizing a 3-0 nylon suture in a simple interrupted fashion.

After achieving delayed primary closure, the surgeon applied an Unna boot and Coban compression. The compression dressing decreases postoperative edema and helps prevent dehiscence. The surgeon applied a new compression dressing on a weekly basis and removed the sutures three weeks after the application.

The patient's wound was almost completely epithelialized except for the proximal portion of the wound, which developed slight dehiscence. The patient continued on compression dressing therapy for another month. The dehisced portion of the wound was completely covered with granulation tissue and had no exposed tendon or bone.

One month after delayed primary closure, the wound had progressed well and had completely healed less than two months after the patient received the device. ■

Dr. Reyzelman is an Assistant Professor and the Chairman of the Department of Medicine at the California School

of Podiatric Medicine at Samuel Merritt University.

Mr. Garukyan is a third-year podiatric medical student at the California School of Podiatric Medicine at Samuel Merritt University.

References

1. Frykberg R, Zgonis T, Armstrong DG, Driver VR, Giurini JM, Kravitz SR, Landsman AS, Lavery LA, Moore JC, Schuberth JM, Wukich DK, Andersin C, Vanore JV. Diabetic foot disorders, a clinical practice guideline. *J Foot Ankle Surg* 2006; 45(5 Suppl):s1-s66.
2. Thomsen TW, Barclay DA, Setnick GS. Basic laceration repair. *N Engl J Med* 2006; 355(17): e18-e22.
3. Kamath JB, Bhardwaj P. A unique method of plantar forefoot ulcer closure using the Ilizarov device: series of 11 patients with leprosy. *Podiatry Internet Journal* 3, 2008. Available at <http://thefootblog.org/2006/12/14/podiatry-online-journal/>
4. Nielson DL, Wu SC, Armstrong DG. Delayed primary closure of diabetic foot wounds using the DermaClose™ RC Tissue Expander. *Podiatry Internet Journal* 2: 2007. Available at <http://thefootblog.org/2006/12/14/podiatry-online-journal/>
5. Armstrong D, Wunderlich R, Lavery L. Reaching closure with skin stretching. *Clin Podiatr Med Surg* 1998; 15(1):109-116.
6. Armstrong D, Sorensen J, Bushman T. Exploiting the viscoelastic properties of pedal skin with the Sure Closure Skin Stretching Device. *J Foot Ankle Surg* 1995; 34(3):247-253.
7. DermaClose™ RC, External Tissue Expander. Available at <http://www.derma-close.com/>. Accessed October 20, 2008.
8. Hanft J, Savard M, Calvo B, et al. Continuous external tissue expander for closure of lower extremity wounds: a case series. Oral abstract, Symposium on Advanced Wound Care, Dallas, Texas, 2009.

Additional References

9. Reyzelman A, Garukyan N, Larkin K, McAloon C. Primary closure of wounds as augmented by DermaClose™ RC: a retrospective study. Pending submission 2009.

Editor's note: For further reading, see "A Guide To Closure Techniques For Open Wounds" in the July 2003 issue, "A Closer Look At Diabetic Foot Infections" in the July 2005 issue, and "A Guide To Transmetatarsal Amputations In Patients With Diabetes" in the July 2006 issue of Podiatry Today.

To access the archives or get information on reprints, visit www.podiatrytoday.com.