Utilization of a New Tissue Expander in the Closure of a Large Mohs Surgical Defect

Amir A. Bajoghli MD,[a] Jane Y. Yoo MPP,[b] Duyen T. Faria DO[c]

[a]Dermatology and Mohs Surgery Section, Inova Fairfax Hospital; George Washington University School of Medicine; Skin & Laser Surgery Center, PC, Falls Church, VA
[b]Virginia Commonwealth University, Richmond, VA
[c]Excel Dermatology, Vienna, VA

ABSTRACT

Background: Malignant proliferating trichilemmal tumor (MPTT) is a rare neoplasm originating in the outer sheath of a hair follicle that often presents as a slowly enlarging, painful, subcutaneous scalp nodule. The authors describe a case of malignant proliferating trichilemmal tumor (MPTT) in an elderly 65-year-old Asian male who presented with a 5.5 x 5.0 cm mass on the posterior scalp.
Methods: The authors present a unique dual approach to treatment of MPTT in both the excision and wound revision phases. First, Mohs micrographic surgery is utilized for more discrete removal of malignant tissue, as opposed to wide excision. Then, a novel device called DermaClose® RC is used in wound revision, a device that has proven to be more effective in promoting wound closure than traditional suturing.
Results: Mohs micrographic surgery was used to excise the tumor in three stages. The resulting irregular wound measured 6.3 x 5.6 cm, and was repaired with the device. Following the application of the device, the wound reduced in size to 1.5–1.0 cm. Post-operatively, the patient had no evidence of recurrent disease at seven months.
Conclusion: Use of the DermaClose RC tissue expander following a Mohs surgical procedure provides an effective functional and cosmetic alternative to a skin graft which creates a donor site wound and creates a more complicated, time consuming procedure. The dual approach discussed here–of Mohs micrographic surgery performed in tandem with wound revision via the tissue expanding device is one that may yield promising benefits but warrants further evaluation.

INTRODUCTION

Malignant proliferating trichilemmal tumor (MPTT) is an uncommon lesion originating in the outer sheath of a hair follicle that often presents as a slowly enlarging, painful, subcutaneous scalp nodule. It is a rare neoplasm often differentiated from its benign counterpart by architectural atypia and clinically aggressive behavior. First described by Mehregan and Lee,[5] more than 30 cases of MPTT have been identified, including 12 cases of metastatic disease.[4]

In terms of its histopathology, unlike its benign counterpart (PTT), MPTT exhibits a histological appearance of nuclear atypia, marked cellular pleomorphism with atypical mitoses, dyskeratotic cells and infiltrating margins.[1,2]

Like benign proliferating trichilemmal tumors (PTT's), traditional management of MPTTs is that of surgical excision with clear margins. However, it is recognized that because the margins of the tumor may extend beyond what is clinically apparent, the use of Mohs micrographic surgery has emerged as a beneficial alternative to wide local excision.[2,3]

Here the authors describe a unique dual approach to treatment of MPTT in both the excision and wound revision phases. First, Mohs micrographic surgery is utilized for more discrete removal of malignant tissue, as opposed to wide excision. Then, a novel device, DermaClose® RC (Wound Care Technologies, Chanhassen, MN), is used in wound revision, a device that has proven to be more effective in promoting wound closure as opposed to traditional suturing.

The novel device is a tissue expander which facilitates closure of wounds up to 15 cm in diameter by continuously expanding the skin around the wound until it has stretched enough to suture the wound edges closed. Once in place, with tension applied, the device requires no additional tightening after its initial application. The device's tension controller applies a constant, measured pulling force as it gently expands the skin around the wound (Figure 1).

FIGURE 1. DermaClose® RC Continuous External Tissue Expander.

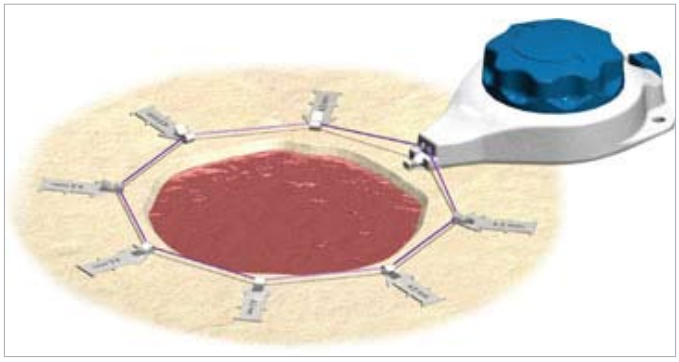

This dual approach is a more effective and satisfying one in several ways. Functionally, there is more certainty about the elimination of malignancy because of the increased accuracy afforded by Mohs microscopic layer-by-layer removal of affected tissue; also, in terms of healing, the device promotes a more natural healing process and thus, a more satisfactory cosmetic resolution as well.

CASE REPORT

The authors describe a case of malignant proliferating trichilemmal tumor (MPTT) in an elderly 65-year-old Asian male who presented with a 5.5 x 5.0 cm mass on the posterior scalp. There was no noted bleeding or ulceration. The lesion had slowly enlarged over the past ten years. The patient was otherwise healthy with no significant past medical history. Review of systems was negative. The tumor was excised using Mohs micrographic surgery and the wound revised, utilizing the above-described device.

Physical Examination

Exam revealed a 5.5 x 5.0 cm pink well-defined nodule with islands of crust on one side (Figure 2). Regional lymphadenopathy was noted. The rest of the physical examination was unremarkable.

Histopathology

Histology depicted a solid cystic epithelial neoplasm composed of cells without distinct intercellular bridges and with abundant eosinophilic cytoplasm (Figure 3). The lobules varied in size and shape, with a confluent pattern. The borders were well-demarcated but jagged and spiky in some foci. The central portion of the cystic areas were compactly orthokeratotic with dyskeratotic cells and calcium. The solid areas had large and crowded nuclei with rare mitotic figures. The asymmetry, marked variation in size and shape of aggregations with confluent growth pattern, as well as nuclear crowding at the periphery, is consistent with MPTT.

FIGURE 2. Malignant proliferating trichilemmal tumor.

Radiographic Findings

PET scan showed no evidence of metastases.

Procedure

Mohs micrographic surgery was used to excise the tumor in three stages. Hematoxylin and eosin stains were used for all microscopic sections, with achievement of clear margins. The resulting irregular wound measured 6.3 x 5.6 cm, and was repaired with the afore-mentioned device.

The area was prepped and infiltrated with 1% xylocaine and epinephrine. Skin anchors, made of 316L surgical stainless steel and penetrating into the subcutaneous tissue, were placed approximately 1.5 cm from the edge of the wound. Each anchor

FIGURE 3. Low power view showing solid portion of the tumor composed of variably sized lobules of basaloid cells with atypical and crowded nuclei and jagged borders.

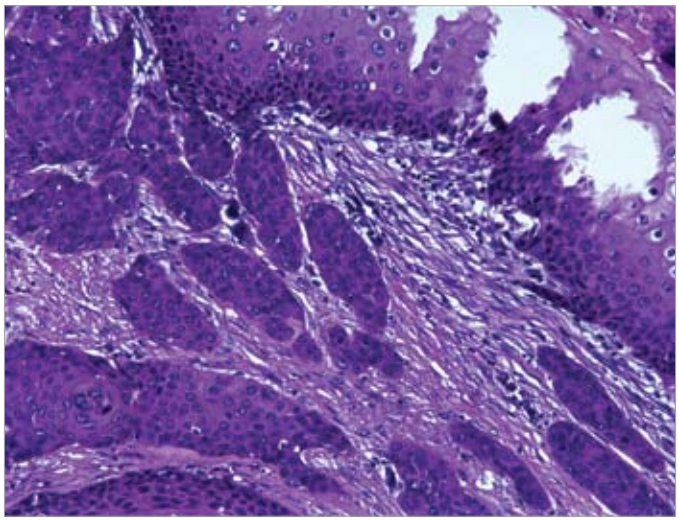

FIGURE 4. Wound after revision with closure.

was stabled twice with a standard skin stapler. Once the anchors were in place, the line from the device's tension controller was attached around each skin anchor and the knob of the tensioning device was rotated until a clutch mechanism provided the audible indication that full tension has been achieved.

Following the application of the device, the wound reduced in size to 1.5–1.0 cm (Figure 4). The wound was dressed with Aquaphor healing ointment and a pressure dressing. The authors proceeded with the removal of the device and to surgically close the wound utilizing 4.0 Vicryl sutures, which were placed across the wound and the device removed (Figure 5). Postoperatively, the patient had no evidence of recurrent disease at seven months (Figure 6).

DISCUSSION

Mohs micrographic surgery has evolved as a superior option for treating MPTT over wide excision due to its tissue sparing technique and the increased ability to assess microscopically the exact tissue margins and extensions, and thus increased probability of eliminating malignancy. Use of the DermaClose RC tissue expander following Mohs surgical procedure provides an effective functional and cosmetic alternative to a skin graft which creates a donor site wound and engenders a more complicated, time consuming procedure. Since the device results in reduced scarring, it and can effectively treat congenital nevis and skin cancers in high tension areas such as the leg, thigh and back. The device can also treat dehisced surgical wounds, excisional wounds, traumatic injuries and chronic wounds once the wound bed is free of devitalized tissue and bacterial contamination.

The dual approach discussed here—of Mohs micrographic surgery performed in tandem with wound revision via the tissue expanding device—is one that may yield promising functional and cosmetic benefits. However, further evaluation is warranted to determine the device's role compared to traditional closures in similar settings.

FIGURE 5. Surgical site one week post-operative.

FIGURE 6. Surgical site seven months post-operative.

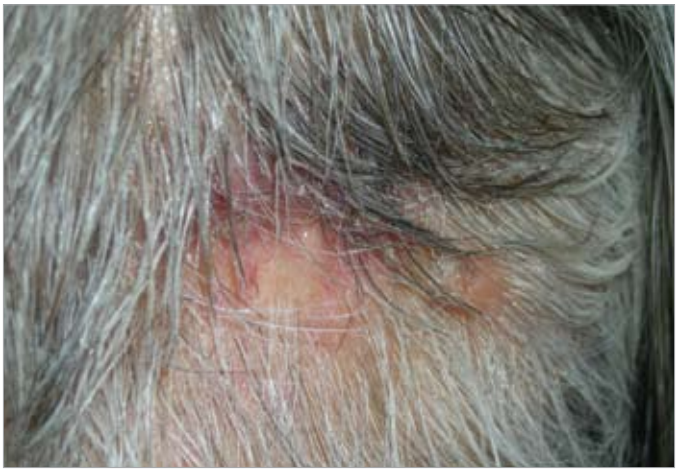

DISCLOSURES

The authors have no relevant conflicts of interest to disclose.

REFERENCES

1. Markal N, Kurtay A, Velidedeoglu H, et al. Malignant transformation of a giant proliferating trichilemmal tumor of the scalp: Patient report and literature review. *Ann Plast Surg*. 1998;41(1):314-316.
2. Satyaprakash AK, Sheehan DJ, Sangueza OP. Proliferating trichilemmal tumors: A review of the literature. *Dermatol Surg*. 2007;33(9):1102-1108.
3. Tierney E, Ochoa MT, Rudkin G, et al. Mohs' micrographic surgery of a proliferating trichilemmal tumor in a young black man. *Dermatol Surg*. 2005;31(3):359-363.
4. Lopez-Rios F, Rodriguez-Peralto JL, Aguilar A, et al. Proliferating trichilemmal cyst with focal invasión: Report of a case and a review of the literature. *Am J Dermatopathol*. 2000;22(2):183-187.
5. Mehregan AH, Lee KC. Malignant proliferating trichilemmal tumors–Report of three cases. *J Dermatol Surg Oncol*. 1987;13(12):1339-1342.

ADDRESS FOR CORRESPONDENCE

Amir A. Bajoghli, MD
8130 Boone Boulevard #340
Tysons Corner, VA 22182-2640
Phone: ..... (703) 893-1114
Fax: ..... (703) 893-4449
E-mail: ..... Mohssurgery@yahoo.com