

Case report: DermaClose successfully used to offload high tension closure of large surgical wound resulting from AAA repair

David Vicente, M.D., Mercy St Anne.

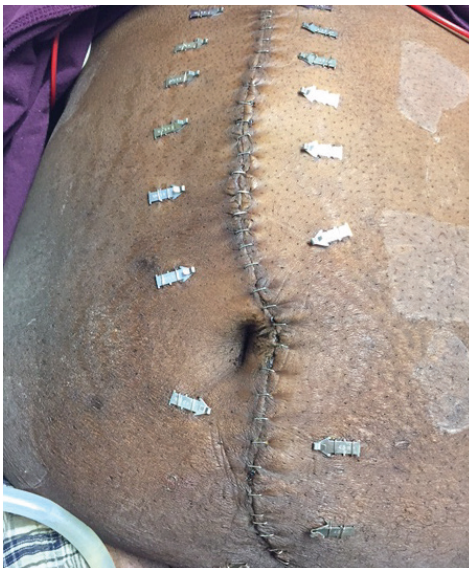Case Report #39

Prior to application of DermaClose: A 43-year-old male with heart failure, diabetes, and obesity was admitted for repair of a 7.8 cm aortic aneurysm.

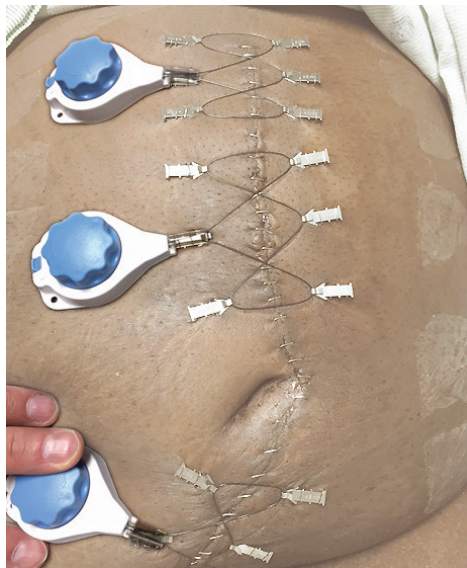
Removal of DermaClose: We removed the DermaClose devices on post op day 5 and the incision remained intact.

DermaClose application: DermaClose application process went smoothly. Throughout the time period that DermaClose was applied the patient reported only mild pain.

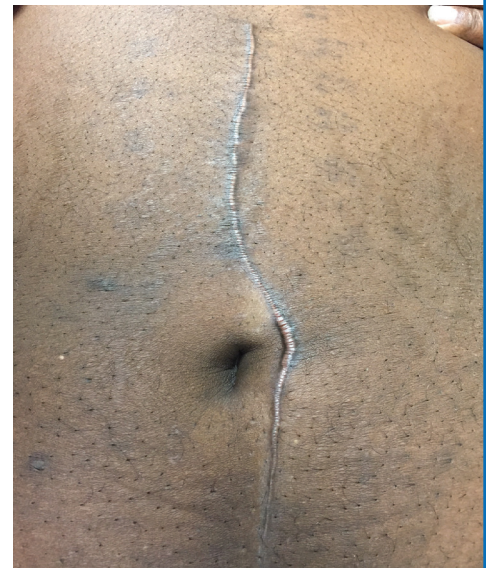
Follow-up: We were very satisfied with the use of DermaClose. At follow-up 6 weeks post DermaClose removal, the patient was healing nicely with the exception of a small keloid which should soon resolve.



DermaClose skin staples applied approximately 3 cm from either side of the high tension incision.



3 DermaClose devices applied using the shoelace technique.



Follow-up at 6 weeks shows the wound healing well.

To schedule a visit by a professional sales representative, please call (800) 896-0436. Learn more at dermaclose.com.