

Charles J. Hastings, DPM, AACFAS - McKenzie-Hastings Institute for Foot & Ankle Surgery, Suffolk, VA; Associate Professor of Surgery, Eastern Virginia Medical School, Norfolk, VA.

This is a 68 y/o poorly controlled diabetic that originally presented to the office complaining of a malodorous foot that was not responding well to 6 weeks of Vaseline on a dead plantar midfoot. The patient was found to be septic and in acute renal failure. He was admitted to the hospital.

A below-knee amputation was recommended to the patient to save his life. The patient wished for limb salvage despite the high risk of limb and/or life loss. The patient underwent revascularization and subsequent Chopart open amputation and VAC therapy.

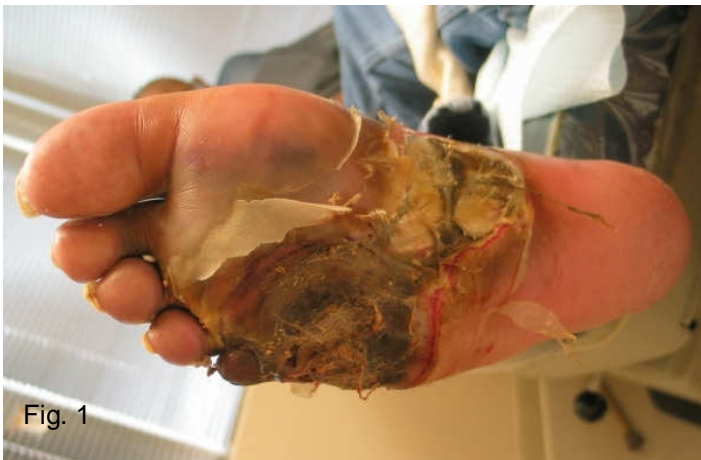

Fig. 1

Initial presentation

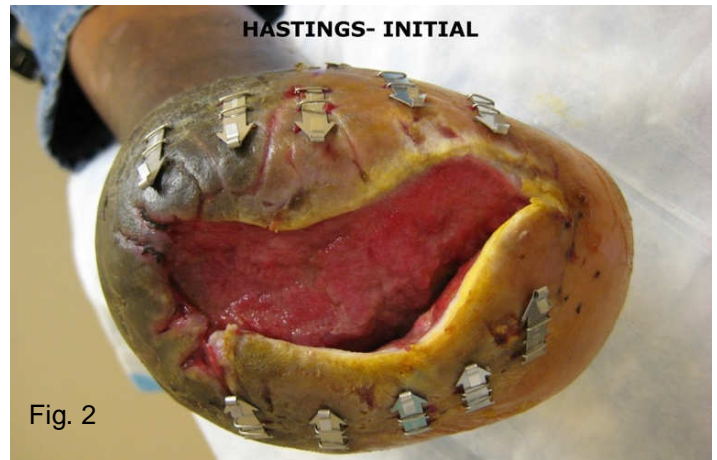


Fig. 2

3.8 cm x 8.5 cm x 2.5 cm

The patient's wound slowly improved over the next four months. On 3/26/08 the DermaClose RC was applied utilizing the shoelace technique and left in place for seven days (fig. 2). Upon the patients return to the office the tissue had fully approximated and the device was removed (fig. 3).

At that time the wound edges and granulation were freshened, and the wound was primarily closed without complication. Six week follow up is shown in figure 4.



Fig. 3

HASTINGS- 7d

7 days post application of DermaClose RC

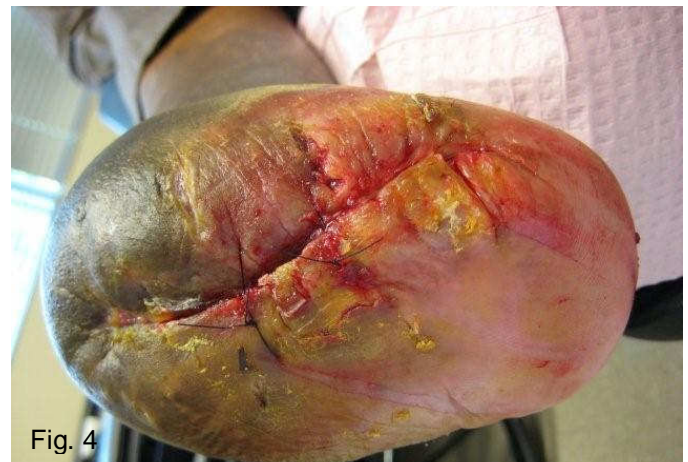


Fig. 4

6 weeks post application of DermaClose RC