Staged Closure of a Giant Omphalocele Using an External Tissue Expander and an Acellular Matrix

Jonathan P. Roach, MD, Stephanie A. Jones, DO,
D. Dean Potter, MD, Denis D. Bensard, MD, David A. Partrick, MD
The Children's Hospital, Aurora, CO, USA

Affiliated with University of Colorado

Background

•Omphalocele presents across a wide spectrum of severity

•Historically these abdominal wall defects have been closed primarily or in a delayed fashion using the sack as a silo or with "escharotic therapy"

•Giant omphalocele precludes fascial closure and limits treatment options

•Rupture of the sack of a giant omphalocele at delivery poses a unique challenge to the pediatric surgeon

Case

•We report the case of a full term male born with a giant omphalocele which ruptured at delivery

•The sac contained all of the small and large bowel as well as the liver

•The abdominal wall defect measured 15 cms and encompassed the entirety of the anterior abdominal wall

•Because fascial closure was not possible we were forced to achieve epidermal closure with a novel combination of therapy

Treatment

•After birth the ruptured omphalocele sack was excised and replaced with a silastic patch which was reduced over the first weeks of the child's life (Image 1).

•Because reduction eventually lead to dehiscence of the silastic silo from the fascia a human dermal matrix was used to replace the fascia and an external tissue expander was used to obtain further reduction and skin coverage (Images 2-4).

•The external tissue expander lead to significant reduction and skin advancement under medical paralysis (Figure 5-6).

•Residual human acelluar dermal matrix became dry and infected and was excised. A vacuum closure device was placed until all tissue was healthy. A porcine acellular matrix and vacuum device were then placed (Figures 7-8).

•Near complete epithelialization was subsequently achieved (Figure 9).

Figure 1

Figure 2

Figure 3

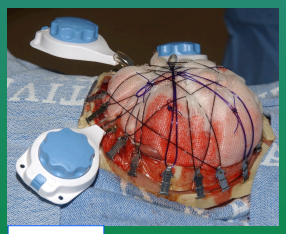

Figure 4

Figure 5

Figure 6

Figure 7

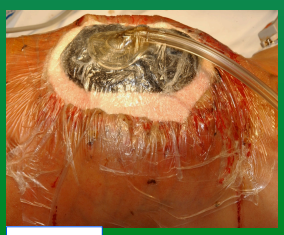

Figure 8

Figure 9

Conclusions

•Giant omphalocele with rupture at birth is a difficult problem for the pediatric surgeon

•Multiple wound treatment modalities may be necessary to achieve skin closure

•Our technique utilizing external tissue expanders and an acellular porcine matrix allowed skin closure and hospital discharge by 7 months of age.